

# Transanal doppler-guided hemorrhoidal artery ligation / recto anal repair (HAL-RAR<sup>®</sup>) for treatment of Grade 3-4 hemorrhoids: a new mini-invasive technology

EUGENY ALEKSEEVICH ZAGRYADSKIY - SERGEY IVANOVICH GORELOV

Medical Coloproctology Center - Moscow, Russia

**Abstract:** Postoperative pain is the main adverse effect of formal hemorrhoidectomy. RAR (Recto Anal Repair) - a new technique based on HAL - Doppler-guided Hemorrhoidal Artery Ligation of the terminal branches of the su-perior hemorrhoidal artery combined with TRM (Transanal Rectal Mucopexy) - is presented as an alternative to hemorrhoidectomy. **Methods:** This non-controlled, prospective study includes 85 patients (male: 57, female: 28, mean age: 44 years) treated for Grade III-IV hemorrhoids. By means of a special new modified proctoscope, the arteries leading to the hemorrhoidal cushions were located in the pain-free area of the rectum above the dentate line and ligated under Doppler guidance. A transanal rectal mucopexy was then performed to lift and secure the hemorrhoidal prolapse back in place. **Results:** Time of operation ranged from 24 to 45 minutes (32±5.21). Postoperative discomfort was measured with a visual analog scale (1-10) and resulted in a mean score of 33.2 ± 0.52 mm (range: 2.1-4.8 mm) on the first day, and a mean score of 16.5 ± 0.10 mm (range: 0-4.0 mm) over five days. Patients were examined at intervals of 6, 8 and 12 months thereafter. The mean follow-up was 10 months (range: 6-12). Bleeding re-solved in 82 patients (96.5 percent), prolapse in 78 patients (91.8 percent). The complication rate was low. **Conclusion:** RAR (Recto Anal Repair) - a combination of Doppler-guided ligation of the hemorrhoidal ar-teries (HAL) with transanal rectal mucopexy (TRM) - is a safe and effective alternative to hemorrhoidectomy, and associated with minimal discomfort and a low risk of complications.

**Key words:** Hemorrhoids; Doppler-guided hemorrhoidal artery ligation; Transanal rectal mucopexy; Prolapse; Rectal bleeding.

## INTRODUCTION

There are several well-established procedures such as Milligan-Morgan,<sup>1</sup> Parks,<sup>2</sup> and Ferguson,<sup>3</sup> which are considered the gold standard in treating Grade III-IV hemorrhoidal disease. Surgical hemorrhoidectomy is a notoriously painful procedure, and much research over the last two decades has concentrated on reducing posthemorrhoidectomy pain resulting from these surgical incisions. This effort has resulted in outpatient treatments such as sclero-therapy,<sup>4</sup> rubber band ligation,<sup>5</sup> Ultroid and Bipolar diathermy coagulation,<sup>6,7</sup> and infrared photocoagulation.<sup>8</sup> This process accelerated the need for "minimally invasive" treatment methods also for the higher Grade III-IV patients. Since November 2003, we have included HAL<sup>9</sup> Hemorrhoid Artery Ligation into our treatment concept because of its minimally invasive approach. The essentials of the operation are the precise and selective ligation of the arteries supplying blood to the hemorrhoids. This technique allows for the restoration of the normal anatomy using minimally invasive surgery with substantially reduced pain and discomfort. In observational studies this treatment has been shown to be efficient in treating Grade II-IV hemorrhoidal diseases.<sup>9-12</sup> In a prospective study, the results of HAL corresponded to those achieved with conventional surgery (Milligan-Morgan).<sup>13</sup> Residual prolapse however, has been reported at 8% for Grade III and 50-60% for Grade IV hemorrhoids.<sup>11</sup> To address this shortcoming, we propose the use of a new technique which is a combination of HAL with transanal rectal mucopexy (TRM) already described by Farag,<sup>27</sup> carried out with a new, modified proctoscope and a special device for lifting and fixing the protruding hemorrhoids.

## PATIENTS AND METHODS

This non-randomized, prospective study includes 85 patients with symptomatic hemorrhoids Grade III-IV treated by RAR (Recto Anal Repair), which is the combination of HAL (Hemorrhoidal Artery Ligation) and TRM (Transanal Rectal Mucopexy), at the Coloproctology Center in Moscow, Russia, over a period of 12 months from January 2007 to January 2008.

## Patient selection

The study includes adult patients only. All patients were subjected to a detailed clinical examination prior to the procedure using rigid sigmoidoscopy and anoscopy for the diagnosis and staging of the disease. Any prolapse which could be reduced was classified as Grade III hemorrhoidal disease. Prolapsing hemorrhoids which could not be reduced were classified as Grade IV. Other underlying pathologies were excluded by barium enema or colonoscopy where necessary. Prior to surgery a photograph of the anal aspect of the patient was taken. Patients with the following conditions were excluded: (1) acute thrombosed hemorrhoids; (2) external hemorrhoids or other concomitant anal diseases (fissure, fistula, or abscess, etc.); (3) inflammatory bowel disease or hematological disorders; (4) anticoagulants; and (5) patients with a previous history of anorectal surgery, including previous hemorrhoidectomy or fistula surgery. The patients belonged to Category I-II of the ASA score (American Society of Anesthesiologists).

## Patient preparation

All patients received a written explanation of the HAL-RAR treatment technique and an informed consent form was obtained. The procedure was approved by the local Ethics Committee and was performed according to the Declaration of Helsinki. Patients were prepared by having an oral intake of fluids from midday before the procedure, and being given two "Microlax" enemas (Kabi Pharmacia AB) two hours before the procedure. One hour before the procedure, Emla ointment (Astra Zeneca, Sweden) was applied to the perineal region and intramuscular butorphanol tartrate (Stadol, Bristol-Myers Squibb) was entered. Prophylactic antibiotics were not routinely prescribed.

## Operative technique

All patients were treated with the same HAL Doppler equipment (HAL-Doppler, A.M.I. Agency for Medical Innovations Ltd, Feldkirch, Austria). The RAR procedure was performed in the lithotomy position under general anesthesia as a day-case or short-stay procedure. General anesthesia was induced with intravenous propofol and the airflow maintained using a laryngeal mask. Intravenous ketorolac

(50 mg) was given at induction. After cleaning the perineal skin region and covering the patient with sterile draping around the perineal area, an anococcygeal ligament block of 5 ml bupivacaine 0.5 percent (Astra Zeneca, Sweden) was performed. After relaxation of muscles and lubrication of the anal canal with electro-conductive gel, the probe (RAR-2011) was inserted to start the search for the hemorrhoidal arteries by means of Doppler technology. The probe was gently rotated to localize hemorrhoidal arteries. Most often 6 arteries were localized in the 1, 3, 5, 7, 9 and 11 o'clock positions (as viewed in the anatomical lithotomy position). The surgery was performed according to the Meintjes modification. At first the arteries at 11 and 1 o'clock were ligated separately. The ligations were performed with a vicryl stitch especially made for this procedure (A.M.I. HAL Suture, 2/0 Vicryl, tapered needle, 5/8 circumference, reinforced needle-thread connection). A double figure-of-eight stitch was placed through the ligation window of the probe and ligated with a knot pusher. Obliteration of the vessels was confirmed by the absence of any Doppler sounds distal to the sutures. The transanal mucopexy was carried out using the RAR probe (RAR-2011) in combination with the special RAR metal sleeve (RAR-2013), by applying longitudinal continuous running sutures in 3-4 quadrants. (The scheme of operation) (Fig. 1).

**Postoperative Management**

Food was allowed in the immediate postoperative period. For pain relief, dologesic was prescribed. Intramuscular Butorphanol tartrat (Stadol, Bristol-Myers Squibb) (1 mg/kg body weight) or ketorolac trometamin (30-60 mg) injections were given on demand. For stool softening, patients received Macrogol 4000 (Forlax, Beaufour Ipsen International) 10 gram 1-2 times a day for 3 weeks. Additionally, we prescribed "Detralex" (micronized purified flavonoid

fraction (Daflon) for all patients 1000 mg/day orally for a period of 3 weeks. For the first 10 days patients were advised to take anti-inflammatory suppositories. Hospital discharge was followed under strict criteria: (1) the patients were fully ambulatory; (2) "Butorphanol tartrat" injection was no longer required; and (3) the patients did not complain of bleeding or urinary retention. Patients were advised not to have physical strain for another 3 weeks.

**Measured Outcomes**

Operative data and postoperative complications were recorded. Postoperative hemorrhage was defined as: (1) when the bleeding required surgical intervention, or (2) when hospital readmission was required. A 100-mm visual analog scale (VAS) - from 0 (no pain) to 100 (the worst pain imaginable) - was used to evaluate the intensity of pain postoperatively. The patient was instructed to score pain according to this. The first pain score was done three hours after the end of the intravenous anesthesia effect. Thereafter, the pain score was obtained daily, from the first to the seventh postoperative day and a mean pain score was calculated. This score thus took into account the intensity and duration of pain. Because the time of maximal pain perceived by different patients might be quite different, a mean pain score is a better reflection of the pain experienced in the first postoperative week. The number of intramuscular "Butorphanol tartrat" and "ketorolac trometamin" injections given during hospitalization, and the total number of dologesic tablets (ketorolac) taken by the patient during and after hospital discharge, were recorded. Other information, including the day of first bowel movement after surgery and the time it took to return to work, was also recorded. To assess postoperative functional outcomes, patients were administered a simple, standardized questionnaire to grade incontinence in accordance with

**The Scheme of the Operation**

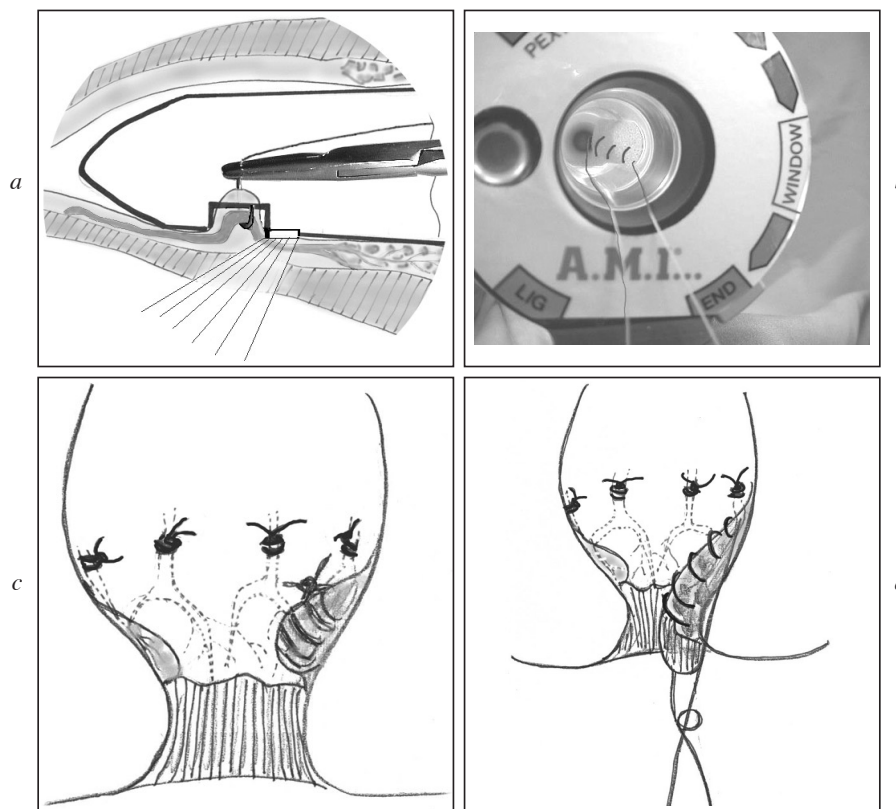


Fig. 1. – a) Doppler-Guided Hemorrhoidal Artery Ligation - HAL; b) Transanal Rectal Mucopexy - TRM - with RAR Probe and RAR Sleeve; c) Continuous running suture; d) Recto Anal Repair - RAR. A combination of HAL and TRM.

TABLE 1. – Characteristics of patients who underwent RAR. Values are mean (SD).

Parameter	Men (n. = 57)	Women (n. = 28)
Age, years	45 (9.1)	44 (8.8)
Disease duration (years)	7 (4.1)	8 (3.0)
Classification of hemorrhoids n. (%)		
Grade III	45 (74)	16 (26)
Grade IV	12 (50)	12 (50)

TABLE 2. – Preoperative symptoms of hemorrhoids.

Symptoms of hemorrhoids	(n. = 85)
<i>Prolapse</i>	
moderate	32 (37.6)*
severe	53 (62.4)
<i>Bleeding</i>	
light	21 (24.7)
moderate	34 (40.0)
severe	18 (21.2)
<i>Anal pain</i>	
light	64 (75.3)
<i>Pruritus/anease</i>	
light	24 (28.2)
moderate	1 (1.2)

(\*) = %

Wexner et al.'s scores. Outpatient follow-up was at 2 weeks, 1, 6, 8 and 12 months after the procedure.

## RESULTS

Doppler guided hemorrhoidal artery ligation (HAL) was introduced to the clinic in November, 2003 to treat patients with hemorrhoidal diseases of Grade II-IV. Since then, 627 patients were treated with this new treatment method DG-HAL. From January 2007 through to January 2008, 85 patients, mean age of 44 (range 27-68) years; male: 57, female: 28, with Grade III-IV hemorrhoids were treated with the new RAR technology. Disease duration: 8 (range 8-18) years (Tab. 1).

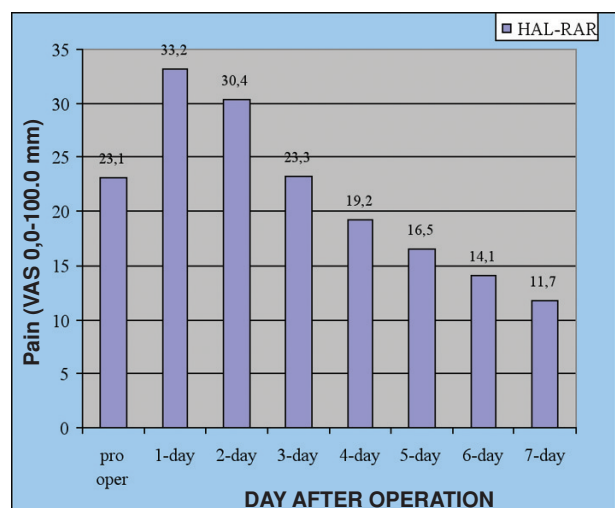


Fig. 2. – Pain scores (visual analog scores -VAS) before (pre-op) and after HAL-RAR mean(SD)

TABLE 3. – Pain score and quantity of analgesics consumption (n. = 85).

Days after operation	VAS mean (SD)	Analgesic requirement «Ketorolac trometamin (mg.) mean (SD)
1 day	33.2 ± 0.52 mm	31.6 ± 0.45 mg
2 day	30.4 ± 0.61 mm	28.7 ± 0.52 mg
3 day	22.3 ± 0.98 mm	17.4 ± 0.10 mg
4 day	19.2 ± 0.10 mm	14.4 ± 0.10 mg
5 day	16.5 ± 0.10 mm	13.3 ± 0.93 mg
6 day	14.2 ± 0.79 mm	–
7 day	11.7 ± 0.81 mm	–

TABLE 4. – Postoperative complications, n. = 85.

Type of complication	Patients	n. (%)
Thrombosis of external hemorrhoids	7	(8.2)
Fever	3	(3.5)
Postoperative bleeding	0	0
Urinary retention	0	0
Total	10	(11.7)

Main symptoms complained of during consultation and found during clinical inspection were prolapsing piles, bleeding, and anal pain (Tab. 2).

The mean time of operation was 32±5.2 (range 24-45) minutes. A postoperative period intramuscular injection “Butorphanol tartrat” was required only in 9 patients (10.5 percent). The pain score on the first and second day was 33.2±0.6 (range 2-5) mm and 30.4±1.9 (range 1-4) mm respectively on a VAS scale. The next days there was a small discomfort which was perceived by patients on a scale VAS from 22.3 ± 0.98mm up to 11.7 ± 0.8 mm on the 7th day. The average need for oral analgesic requirement from day 1 to 3 was 31.6±0.45 mg and 17.4±0.1 mg ketorolac. Hospital stay: 19.3± 2.17 (range 16-23) hours (Figs. 2, 3; Tab. 3).

First defecation: 1.6±0.4 (range 1-2) days after surgery. All patients complained of insignificant post-defecation pain which lasted for an average of 5-10 minutes after the first bowel movement.

None of the patients had any complaint of fecal incontinence. Time of return to work: 2.79 ± 0.81 (range 2-4) days.

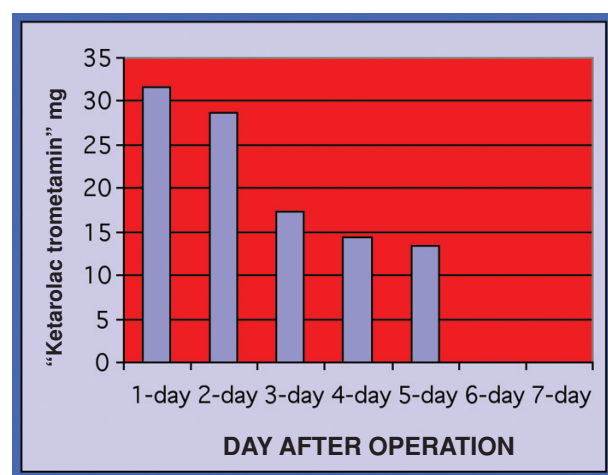


Fig. 3. – Analgesic requirements after HAL-RAR mean(SD).

TABLE 5. – Clinical results ten months after operation (Questionnaire).

Symptom	Before operation	After operation
<i>Prolapse</i>		
not present		78 (91.8)*
light		
moderate	32 (37.6)	1 (1.2)
serious	53 (62.4)	6 (7.1)
<i>Bleeding</i>		
not present	12 (14.1)	82 (96.5)
light	21 (24.7)	3 (3.5)
moderate	34 (40.0)	–
serious	18 (21.2)	–
<i>Defecation pain</i>		
not present	21 (24.7)	85 (100)
light	64 (75.3)	–
<i>Thrombosis external hemorrhoid</i>		
present	7 (8.3)	–
not present	78 (91.7)	85 (100)
<i>Perianal soiling</i>		
not present	63 (74.1)	81 (95.3)
light	21 (24.7)	4 (4.7)
moderate	1 (1.2)	–
<i>Pruritus/anease</i>		
not present	60 (70.6)	–
light	24 (28.2)	–
moderate	1 (1.2)	–

(\*) = %

Postoperative complications were recorded in 10 patients (11.7 percent), swelling and external hemorrhoidal thrombosis in 7 patients (8.2 percent). This complication was stopped conservatively by local therapy. Three patients (3.5 percent) suffered hyperthermia which passed independently. The hyperthermia was probably connected to an operational trauma as it passed independently and did not demand antibiotics. Complications such as secondary hemorrhage, urinary retention, incontinence, and anal stenosis were not recorded. Patients were examined at 2 weeks, and then at 1, 6, 8 and 12 months thereafter. The mean follow-up was 10 (range, 6-12) months. Up to January 2008 all patients had a clinical anoscopic inspection within 6 to 12 month after treatment. In addition, a standardized questionnaire was used [16] (Tab. 4).

A survey on 85 patients, 10 month after the RAR treatment achieved the clinical results shown in Table 5. Bleeding resolved in 82 patients (96.5%), some bleeding was recorded in three patients (3.5%). Prolapse was eliminated in 78 patients (91.8 percent), remaining prolapse was seen in seven patients (7.1%). It was treated by 2 sclerotherapy sessions. 6 patients (7.1%) were complaining about hemorrhoidal prolapse but were diagnosed as having skin tags. The skin tags were removed under local anesthesia. Four patients reported perianal soiling due to functional insufficiency of the anal sphincter attributed to constant prolapsed hemorrhoids.

#### DISCUSSION

Surgical hemorrhoidectomy Milligan-Morgan,<sup>1</sup> Parks<sup>2</sup> and Ferguson<sup>3</sup> are considered to be the gold standards in treating hemorrhoidal disease Grade III-IV. Much research

over the last two decades has concentrated on reducing post-hemorrhoidectomy pain resulting from this surgical procedure. Research has been concentrated in two areas: modification of the technique of surgical hemorrhoidectomy; and the use of a variety of surgical instruments in the hopes of decreasing postoperative pain.<sup>17</sup> Modifications of the surgical technique have included open, semi-open,<sup>6</sup> and closed incisions,<sup>18</sup> routine performance of lateral internal sphincterotomy,<sup>19</sup> and the use of stapling devices<sup>20</sup> (both linear and circular). No technique has been conclusively demonstrated to be superior.<sup>21-23</sup> Laser hemorrhoidectomy gained widespread publicity, but has never been conclusively demonstrated to be superior to conventional hemorrhoidectomy.<sup>24-25</sup> The new representation about pathogenetic hemorrhoidal diseases is based on a role of pathologic arterial flow through arteriovenous anastomoses, and the dystrophic phenomena in the muscular fibroplastic supportive tissue of the inferior hemorrhoidal plexus (Parks ligament) which degenerates with a patient's age. As a result, the mobility of the plexus increases in relation to the intrarectal pressure. The enlarged plexus hemorrhoidalis and the increased mobility caused by insufficient supportive structures are the reason for prolapsing piles. This results in an imbalance between arterial inflow and venous return. The HAL technique<sup>9</sup> aims specifically at interrupting the arterial flow to the hemorrhoids, thought to be a main factor in the etiology. By reducing the inflow, the plexus diminishes and the hemorrhoids shrink. This seems especially effective in Grade II and III hemorrhoids. The Doppler probe allows an accurate localization of all the arteries, which are individually ligated with figure-of-eight sutures. This serves to bunch up the mucosa, which results in a pulling-up of the prolapse while interrupting the blood supply. The HAL technique results in minimal postoperative discomfort but no pain in comparison with hemorrhoidectomy. After five years of HAL hemorrhoidal artery ligation experience on Grade III-IV patients, it became clear to us that reduction of blood supply into the hemorrhoidal plexus reduces the size of the prolapse but the prolapse does not always fully disappear. RAR - a combination of HAL and additional plication sutures (TRM) described by Farag<sup>27</sup> to reposition and fix hemorrhoidal prolapse - demonstrates successful results also for the higher grade hemorrhoid patients. The new modified HAL-RAR proctoscope allows this combination of HAL and TRM (ligation-anopexy)<sup>14</sup> for treatment of protruding hemorrhoids, and also allows the pathogenetic resolution of the basic symptoms of the disease. The use of RAR will lower or eliminate invasive operations, it is a painless and minimally invasive technique that offers an excellent alternative to hemorrhoidectomy. The short hospital stay, low complication rate, and minimal postoperative pain make the RAR procedure ideal for 1-day surgery. Furthermore, it is in accordance with the requirements of minimally invasive surgery.

#### REFERENCES

1. Milligan ETC, Morgan CN Joones LE, et. al. Surgical anatomy of the anal canal, and the operative treatment of haemorrhoids. *Lancet* 1937; 2: 1119-24.
2. Parks AG. Surgical treatment of haemorrhoids. *Br J Surg* 1956; 43: 337-351.
3. Ferguson JA, Mazier WP, Ganchrow MI, Friend WG. The closed technique of hemorrhoidectomy. *Surgery* 1971; 70: 480-484.
4. Graham-Stewart CW. Injection treatment of haemorrhoids. *BMJ* 1962; 1: 213-226.
5. Barron J. Office ligation treatment of hemorrhoids. *Dis Colon Rectum* 1963; 6: 109-113.



6. Dennison AR, Whiston RJ, Rooney S, et al. The management of hemorrhoids. *Am J Gastroenterol* 1989; 84: 475.
7. Hinton CP, Morris DL. A randomized trial comparing direct current therapy and bipolar diathermy in the outpatient treatment of third-degree hemorrhoids. *Dis Colon Rectum* 1990; 33: 931.
8. Neiger A. Infrared-photo-coagulation for hemorrhoids treatment. *Int. Surg* 1989; 74: 142-143.
9. Morinaga K, Hasuda K, Ikeda T. A novel therapy for internal hemorrhoids: ligation of the hemorrhoidal artery with a newly devised instrument (Moricorn) in conjunction with a Doppler flowmeter. *Am J Gastroenterol*. 1995; 90: 610-613.
10. Sohn N, Aronoff JS, Cohen FS, Weinstein MA. Transanal hemorrhoidal dearterialization is an alternative to operative hemorrhoidectomy. *Am J Surg* 2001; 182: 515-519.
11. Arnold S, Antonietti E, Rollinger G and Scheyer M. Doppler ultrasound assisted hemorrhoid artery ligation. A new therapy in symptomatic hemorrhoids. *Chirurg* 2002; 73: 269-73.
12. Narro JL. Hemorrhoid Therapy with Doppler Guided Hemorrhoidal Artery Ligation via Proctoscope KM-25. A New Alternative to Hemorrhoidectomy and Rubber Band Ligation? *Zentralbl Chir* 2004; 129: 208-10.
13. Bursics A, Morvay K, Kupcsulik P and Flautner L. Comparison of early and 1-year follow-up results of conventional hemorrhoidectomy and hemorrhoid artery ligation: a randomized study. *Int J Colorectal Dis* 2004; 19: 176-80.
14. Hussein AM. Ligation-anopexy for treatment of advanced hemorrhoidal disease. *Dis Colon Rectum* 2001; 44: 1887-1890.
15. Jorge JMN, Wexner SD. Etiology and management of fecal incontinence. *Dis Colon Rectum* 1993; 36: 77.
16. Guenin M-O, Rosenthal R, Beatrice Kern B, Peterli R, et al. Ferguson Hemorrhoidectomy: Long-Term Results and Patient Satisfaction After Ferguson's Hemorrhoidectomy. *Dis Colon Rectum* 2005; 48: 1523-1527.
17. Lacerda-Filho A, Cunha-Melo JR. Outpatient haemorrhoidectomy under local anaesthesia. *Eur J Surg* 1997; 163: 935-40.
18. Ho YH, Seow-Choen F, Tan M, Leong AF. Randomized controlled trial of open and closed haemorrhoidectomy. *Br J Surg* 1997; 84: 1729-30.
19. Mathai V, Ong BC, Ho YH. Randomized controlled trial of lateral internal sphincterotomy with haemorrhoidectomy. *Br J Surg* 1996; 83: 380-2.
20. O'Bichere A, Laniado M, Sellu D. Stapled haemorrhoidectomy: a feasible day-case procedure. *Br J Surg* 1998; 85: 377-8.
21. Hosch SB, Knoefel WT, Pichlmeier U, et al. Surgical treatment of piles: prospective, randomized study of Parks vs. Milligan-Morgan hemorrhoidectomy. *Dis Colon Rectum* 1998; 41: 159-64.
22. Patel N, O'Connor T. Suture haemorrhoidectomy: a day-only alternative. *Aust N Z J Surg* 1996; 66: 830-1.
23. Seow-Choen F, Low HC. Prospective randomized study of radical versus four piles haemorrhoidectomy for symptomatic large circumferential prolapsed piles. *Br. J. Surg* 1995; 82: 188-9.
24. Ui Y. Anoderm-preserving, completely closed hemorrhoidectomy with no mucosal incision. *Dis Colon Rectum* 1997; 40 (Suppl): S99-S101.
25. Left EI. Hemorrhoidectomy-laser vs. nonlaser: outpatient surgical experience. *Dis Colon Rectum* 1992; 35: 743-6.
26. Smith LE. Hemorrhoidectomy with lasers and other contemporary modalities. *Surg Clin North Am* 1992; 72: 665-79.
27. Farag AE. Pile suture: a new technique for the treatment of hemorrhoids. *Br J Surg* 1978; 65: 293-295.

*Correspondence to:*

ZAGRYADSKIY EUGENY ALEKSEEVICH  
Medical Coloproctology Center  
Moscow, Russia  
Tsvetnoy bulvar 30 building 2, 103051 Moscow, Russia  
Tel./fax: +7 (095) 208 42 52  
E-mail: Proctolog52@rambler.ru